



E-ISSN: 2320-7078

P-ISSN: 2349-6800

JEZS 2018; 6(6): 603-605

© 2018 JEZS

Received: 12-09-2018

Accepted: 13-10-2018

**Dipali Parmar**

Veterinary Officer,

Department of Animal

Husbandry, Himachal Pradesh,

India

## Clinical management of retention of placenta in murrah graded buffalo with cervico-vaginal postpartum prolapse

**Dipali Parmar****Abstract**

Prolapse and retained fetal membranes are among one of the most commonly occurring pathologies following parturition in animals. CVP normally occurs in dairy cattle during the last trimester of gestation and is more common among buffaloes. A field case of retention of the placenta with mild CVP in murrah graded buffalo is presented and discussed, which was adequately managed by manual repositioning of the prolapsed mass followed by placenta removal. Various factors that predisposed to the prevailing conditions as ruled out from owner history and animal examination was imbalance/deficiency of various minerals and vitamins. Additionally, an animal was reared on the inclined uneven sloping floor which further aggravated the condition. Three day treatment protocol with systemic antibiotics, anti-inflammatory and supportive therapy helped in the full recovery of the animal. However, owner's history, awareness and early reporting of the case were helpful for proper prognosis.

**Keywords:** Buffalo, cervico-vaginal prolapse, retention of placenta, mineral/vitamin imbalance, management

**1. Introduction**

Retention of the placenta is one of the most common and widely occurring obstetrical problems among the dairy herd. It mainly occurs following parturition when placental membranes are not expelled naturally for about 8-12 hours. Prolonged straining accompanied with frequent expulsive efforts by the animal leads to cervico-vaginal postpartum prolapse [2]. It is a pathological condition and if not reported well in time may lead to endometritis, metritis, puerperal metritis and infertility.

Primary cause of retained placental membranes is the failure of fetal cotyledons to detach from maternal caruncles. Various processes involved in the placenta expulsion are the combination of many factors and begin much earlier before actual parturition. Many hormonal and mechanical factors are involved in placenta expulsion, if these fail it leads to the development of the condition followed by a prolonged third stage of labour. Deficiency of endogenous oxytocin along with excess of oestrogen [3] and cortisol predispose to disease development [4, 8]. Higher incidence rate has been reported in buffaloes i.e. 1.2-33.8% when compared to cattle 2.3-11%. Various deficiencies/imbalance of minerals (Calcium, Phosphorous and Iodine), vitamins (Vitamin A), uterine inertia, chronic wasting diseases, genital disorders and various other infectious causes are associated with this condition [8].

Treatment includes proper management of the prolapsed mass followed by manual removal of the placenta. Systemic administration of antibiotics and anti-inflammatory along with supportive therapy is must. Mineral and vitamin deficiencies should be checked and treatment should be adopted accordingly.

**2. Case history and observations**

Murrah graded buffalo, aged about 6 years with the history of calving about 24 hours before was presented with mild cervico-vaginal prolapse along with retained placental membranes. Mild, intermittent straining was present which led to the protrusion of pinkish red mass from the vulvar region. Placenta was seen hanging up to the level of the hock joint (Figure- 1, 2).

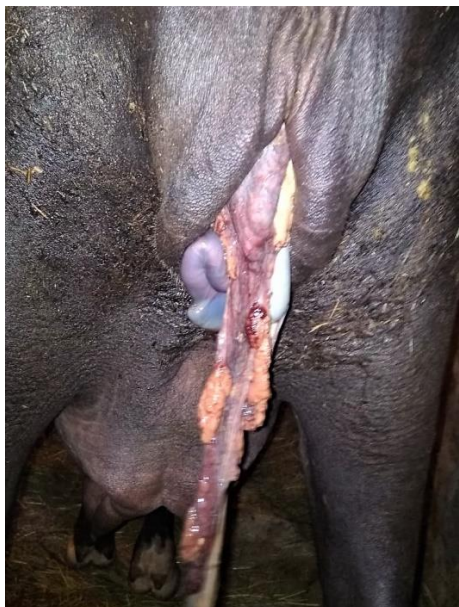
**Correspondence****Dipali Parmar**

Veterinary Officer,

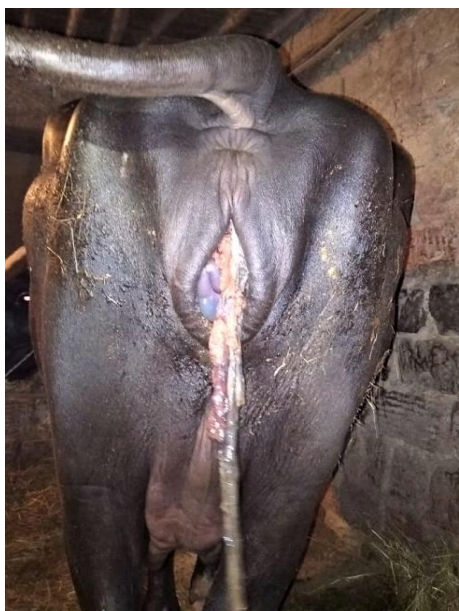
Department of Animal

Husbandry, Himachal Pradesh,

India



**Fig 1:** Vulvar region of the animal after parturition showing prolapsed mass along with retained placental membranes.



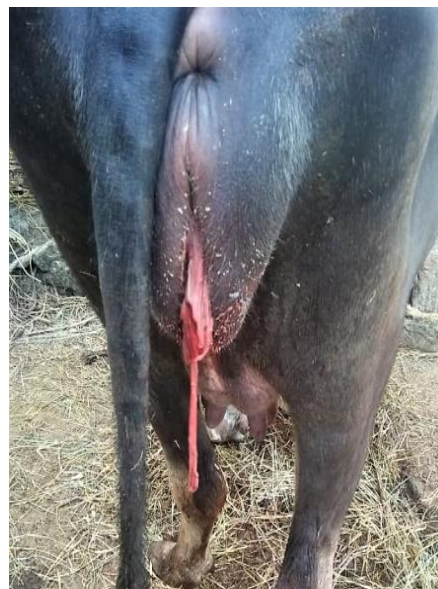
**Fig 2:** Retained placenta hanging upto the level of the hock joint (>24 hours post partum).

On clinical examination body temperature of 101.2°C with normal respiration and tachycardia was observed. Animal was restless and was offed from last 6-8 hours. Fetid odour developed since the placenta begun to macerate and degenerate. No calcium supplementation and mineral feeding was practised by the owner which led to weakness in animal. Animal was raised on inclined un-even floor which led to further development of prolapse condition in latter stages of postpartum.

### 3. Treatment and management

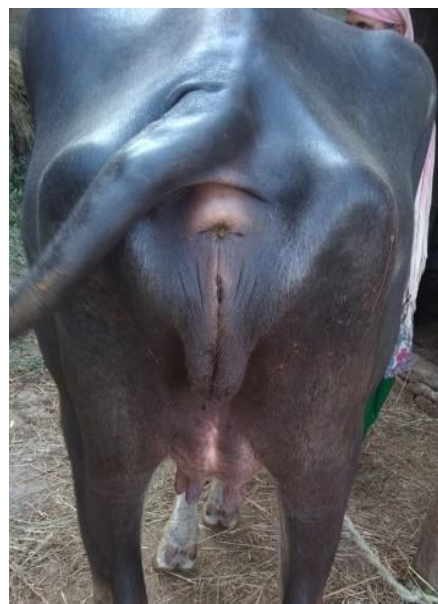
After proper restraining, hindquarters of animal were washed with 0.1% potassium permanganate solution thoroughly. Epidural anaesthesia at lumbo-sacral junction with 2 % lignocaine hydrochloride (6 ml) was given through sterilized syringe in aseptic manner. Hanging foetal membranes were cut with a sterile scissors and prolapse mass was washed with cold water to reduce inflammation and size (Figure- 3). After

this prolapsed mass was packed and lubricated with soframycin ointment and Zinc oxide paste and was slowly redirected in place with mild gentle even pressure. Following repositioning of the prolapsed mass, placenta was slowly pulled out manually by rolling in fist and was removed. No forced traction was done to ensure proper recovery and to avoid bleeding. Herbal replanta powder @ 50 gram oral for two days was advised to effectively remove any left out portion of foetal membrane inside the uterus.



**Fig 3:** Repositioning of prolapsed mass along with cutting of the hanging portion of the placenta.

Supportive therapy with antibiotics (Inj. Ceftriaxone @10mg/kg body weight), anti-inflammatory (Inj. Meloxicam @0.5mg/kg body weight), calcium-phosphorus supplement (Inj. Cal BD, T- Phos), liver tonics (Inj. Belamyl) was given. Follow up of the following treatment was carried out for three days with routine examination of the animal condition. Mineral mixture (Agrimin) and calcium (Osteovet) supplementation was advised to the animal to overcome deficiency and energy deficit (Figure- 4).



**Fig 4:** Full recovery of the animal following three days post treatment, showing normal hind region of the affected animal.

Various complications are associated with the above mentioned pathological condition which includes delayed involution, increased time to subsequent conception <sup>[6]</sup>, decreased pregnancy and conception rates, dystocia, mastitis with reduced milk production.

#### 4. Results and discussion

CVP along with placenta retention is a rare clinical case occurring following parturition. CVP has been reported in the last trimester of pregnancy <sup>[9]</sup> due to the imbalance of estrogen to progesterone ratio in the blood. Due to relaxation of perianal ligaments, vulvar area widens up allowing escape of visceral organs. The prolapsed mass hangs out and if not accurately managed, may be serious affecting future productivity of the animal. Various other risk factors involved are shortened gestation period, dystocia, twinning, abortions, caesarean section, immunosuppression, various infectious agents and multiple hormonal and biochemical changes that occur during entire gestation period in the animal.

Predisposing factors that contribute to prolapse in ruminants are the long myometrium attachments, violent straining, low plane of nutrition, hypocalcaemia, lack of exercise, relaxed atonic flaccid uterus and extreme laxity of the perineum and vulvar lips etc <sup>[3, 7]</sup>.

Following case was effectively managed by repositioning of prolapsed mass and manual removal of placenta along with chemotherapy and supportive treatment <sup>[1]</sup>. However in delayed cases of >24 hours and in high body temperature conditions, manual removal is not recommended as cervix begins to close and there are increased chances of development of septicaemia. Use of epidural analgesia was very effective in the present case as it reduced straining by animal therefore prolapsed mass was retained inside after repositioning thus aiding in better prognosis.

Early reporting with proper history and awareness of owner helped in full recovery of the animal. Overall improvement in the condition of the animal was observed with a gradual increase in overall milk yield.

#### 5. Conclusion

Incidence of postpartum diseases is very common in dairy cows and buffaloes which contribute to infertility and increased risk of culling, thereby making their prevention and management extremely important <sup>[5]</sup>. A rare case of CVP along with ROP presented and discussed was adequately managed and treated with antibiotics, anti-inflammatory and supportive therapy. It was observed that negative energy balance along with parturition stress and exhaustion led to the development of the following condition. To overcome energy deficit and for proper parturition to occur, avoiding any obstetrical problem, high and good quality of feed/fodder with adequate calcium-phosphorus balance and other trace minerals particularly iodine supplementation should be practised. Additionally, control of reproductive diseases is important for minimizing use of antibiotics and other drugs thereby ensuring safe, wholesome and nutritious product.

#### 6. References

1. Aal-Said AH. Some Protocol Treatments for Retained Placenta in local Iraqi Buffalo (*Bubalus bubalis*). Al-Anbar Journal of Veterinary Sciences. 2014; 7(1):39-43.
2. Ahuja AK, Dogra P, Shivkumar S, Dhindsa SS, Singh H. A case of Dystocia due to Fetal Ascites in Murrah Buffalo. International Journal of Environment,

- Agriculture and Biotechnology. 2017; 2(4).
3. Ahuja AK, Singla VK, Singhal S, Kumar S. Management of post-partum bilateral uterine prolapse in a cross bred cattle: A case report. Haryana Veterinarian. 2016; 55(2):239-40.
4. Arthur GH, Noakes ED, Pearson H, Parkinson TJ. Veterinary Reproduction and obstetrics, 6th ed. Harcourt (India) Private Ltd. New Delhi, 1989, 134-140.
5. Gilbert RO. Management of reproductive disease in dairy cows. Veterinary Clinics: Food Animal Practice. 2016; 32(2):387-410.
6. Holt LC, Whittier WD, Gwazdauskas FC. Early postpartum reproductive profiles in Holstein cows with retained placenta and uterine discharges. Journal of Dairy Science. 1989; 72:533-539.
7. Kumbhar UB, Suryawanshi AA, Mulani JB, Raghuvanshi DS. Clinical management of post-partum eversion of uterus in Marathwadi buffalo. Veterinary World. 2009; 1; 2(5):202.
8. Roberts SJ. Veterinary obstetrics and genital Diseases (Theriogenology), 2nd ed. CBS Publishers and Distributors, India, 1971, 189-196.
9. Sah SK, Nakao T. Some characteristics of vaginal prolapse in Nepali buffaloes. Journal of Veterinary Medicine and Science. 1971; 65(11):1213-1215.